


PATIENT

Wally Suknot

SPECIES

Feline

BREED

DSH

SEX

Male Neutered

AGE

4 years

WEIGHT

11.3lbs

INTERPRETED BY

 Maggie Machen Lamy,
 DVM, DACVIM
 (Cardiology)

IMAGING PERFORMED BY

 Dana Alterman,
 RDCS, LVT

HOSPITAL NAME

Eubank Animal Clinic

REFERRING VET

Dr. Kincade

INVOICE

28626

DATE

1/30/23

PRESENTING CLINICAL SIGNS

History: Coughing for 1-2 weeks when rough-housing. Grade 2/6 left parasternal murmur with synchronous pulses. FeLV/FIV/HW all negative

-Radiographs: Show mild bronchointerstitial pattern consistent with chronic lower airway disease.

-Abnormal PE/Chem/CBC/UA Results: 35% - low for this altitude.

ECHOCARDIOGRAM FINDINGS

2D, m-mode, color flow and doppler imaging is available. The left ventricular wall is normal in dimension. There is a mildly hyperechoic endocardium consistent with mild fibrosis. The papillary muscles are normal in size and hyperechoic. The endocardium appears normal. The left atrium is normal in size. The right atrium is normal in size. The right ventricle appears normal. The mitral valve is normal in structure and mobility. Normal flow through both the RVOT and LVOT. Trivial TR. No MR. No AI or PI. No pleural or pericardial effusion seen. No obvious cardiac tumors.

CARDIAC CHART

| FELINE CARDIAC PARAMETERS | BODY WEIGHT (kg) | HR (BPM) | IVSd (cm) <small>(Moise, Pipers)</small> | LVIDd (cm) <small>(Moise, Pipers)</small> | LVWd (cm) <small>(Moise, Pipers)</small> | FS (%) | EF (%) |
|---------------------------|--------------------------------|---------------------------------------------------|------------------------------------------------------------|----------------------------------------------|---------------------------------------------|----------------------------------|-------------------------------|
| NORMAL PARAMETER | ----- | 150-240 | 0.35-0.55 | <2 (mean 1.5) | 3.5-0.55 | 35-67 | 80-100 |
| PATIENT | 5.1 | NM | 0.47 | 1.4 | 0.43 | 56 | 90 |
| FELINE CARDIAC PARAMETERS | LA/AO <small>(Boon)</small> | LA/AO HEART BASE (Swe) <small>(Abbott)</small> | LA 2D short axis Base view (cm) <small>(Abbott)</small> | | LVOT VEL <small>(m/s)</small> | RVOT VEL <small>(m/s)</small> | E max <small>(m/s)</small> |
| NORMAL | <1.5 | <1.3 | <1.2 | | <1.6 | <1.3 | <0.9 |
| PATIENT | NM | 1.2 | 1.1 | | 1.2 | 1.2 | NM |

**Note: All measurements based upon multi-modal images and methods. An average value is reported.*
 Adapted from June Boon, Veterinary Echocardiography, 1998
 Abbott J & MacLean H JVIM 2006;20: 111-119, Moise et al. Am J Vet Res 47:1476, 1986. Pipers et al. Am J Vet Res 40:882, 1979.

INTERPRETATION OF THE FINDINGS & FURTHER RECOMMENDATIONS

Overtly normal cardiac structure and function. The LV wall thickness is normal and there is no evidence of elevated left atrial pressure. No cause for the murmur is identified in this study, making it likely physiologic in origin. No additional issues are identified.

Given these findings, the cough is certainly noncardiac in origin. Consider a course of Azithromycin to cover infectious bases. No medications are indicated. It is important to note that phenotypic HCM can develop at any phase of life in cats (particularly in this predisposed breed), and often does not accompany a heart murmur or PE abnormalities. Periodic screening is ideally recommended in all cats.

No cardiac contraindication for general anesthesia at this time.

Recommend recheck echocardiogram in 1 year to screen for any development of disease that the preexisting murmur may mask.



PATIENT

Wally Suknot

SPECIES

Feline

BREED

DSH

SEX

Male Neutered

AGE

4 years

WEIGHT

11.3lbs

INTERPRETED BY

Maggie Machen Lamy,
DVM, DACVIM
(Cardiology)

**IMAGING
PERFORMED BY**

Dana Alterman,
RDCS, LVT

HOSPITAL NAME

Eubank Animal Clinic

REFERRING VET

Dr. Kincade

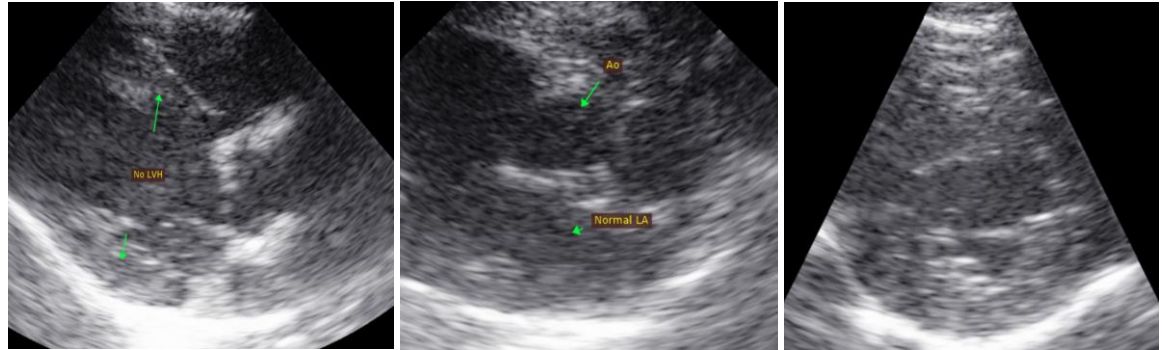
INVOICE

28626

DATE

1/30/23

IMAGES



The information and recommendations provided are based on the images presented by the referring veterinarian. No evaluation can be communicated regarding pathology that was not visible in the image/video clips provided.

Thank you for this referral. This report was generated using transcription software, and minor dictation errors may be present. If the clinical or image interpretation does not parallel your findings or if I can be of any further assistance, please contact me.

Maggie Machen Lamy, DVM
Diplomate of the American College of Veterinary Internal Medicine (Cardiology)
info@sonopath.com